

## Surgery Better Cost Effective Treatment Option for Chronic Ruptured Contained Abdominal Aortic Aneurysm

Nagre SW\*, Bhosle KN, Bendre S, Vignesh R

Cardiovascular & Thoracic Surgery, Grant Medical College, Mumbai, India

\* **Corresponding author:** Cardiovascular & Thoracic Surgery, Grant Medical College, Mumbai, India, Tel: 9967795303; E-mail: surajnagre@yahoo.com

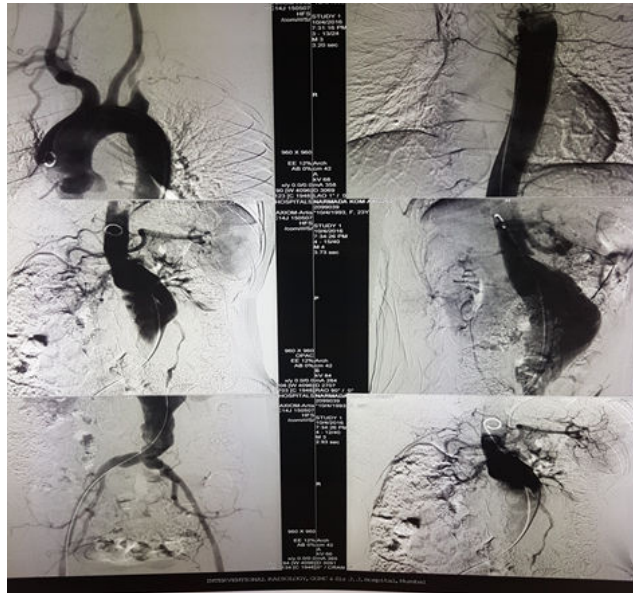### Clinical Presentation

We report a case of a 27 year-old indian female who presented with a 6 month history of low back pain and a mass per abdomen. Patient also had earlier history of pulmonary kochs ten years back for which she received six months of antitubercular therapy. On examination, she had a pulsatile expansile abdominal mass with good femoral and distal pulses. The rest of the examination was normal with good cardiac and respiratory status. Further lab workup including a complete blood count, renal function, liver function, coagulation profile, and erythrocyte sedimentation rate (ESR) were normal except for an elevated C-reactive protein (CRP) of 26. The initial contrast enhanced CT scan with an aortogram demonstrated a 8 × 8 cm partially thrombosed pseudoaneurysm just after the origin of superior mesenteric artery extending to both the common iliac artery origin (Figure 1). The length of the aneurysm was approximately 12.5 cm of the aorta and 0.5 cm of the common iliac arteries. CT also showed involvement of both renal arteries origin in the aneurysm. Although it was suspected, whether or not the aorta was involved in the infective process or even ruptured with a contained hematoma was a question yet to be answered.

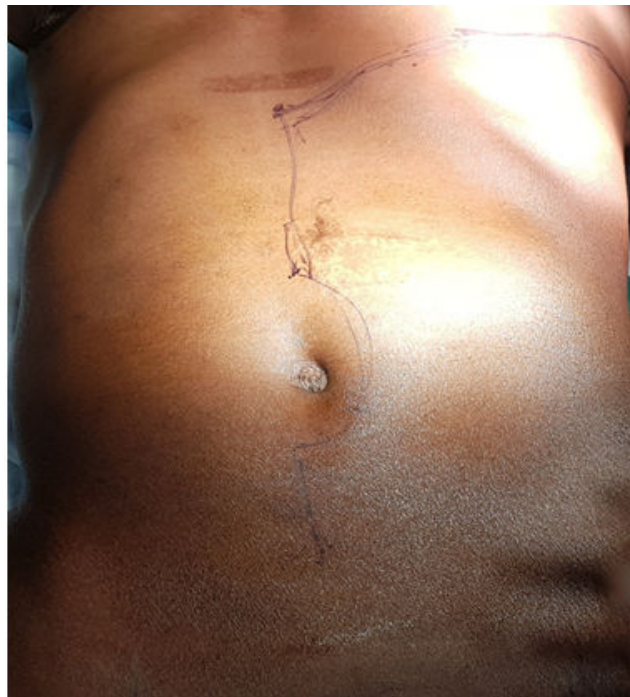We have two treatment option hybrid approach (surgical bypass Y grafting of both renal arteries from external iliac artery followed by stenting of abdominal aorta by interventional radiologist) and other option is total open surgical. But the patient is not affording for hybrid treatment as stent is costly so decision taken for total surgical repair of the abdominal aortic aneurysm. Nevertheless, the possibility of aortic wall infection and abdominal sepsis required careful pre-operative planning and the need to keep both the renal arteries perfused during the entire surgery was planned preoperatively.

A left thoraco abdominal anterior approach was undertaken (Figure 2). The descending thoracic aorta was exposed in the thorax and the diaphragm was cut (Figure 3) and mobilized with releasing posterior crux to gain control of the descending thoracic aorta for the aorto femoral bypass. Left kidney mobilized and renal artery looped (Figure 4). As first step left common iliac artery to left renal artery grafting (Figure 5) was done using 6 mm PTFE graft by 6-0 prolene suture for maintaining its blood supply after clamping descending thoracic aorta (Figure 6). Abdominal aortic aneurysm assessed all around (Figure 7). After 300 iu/kg heparinisation the descending thoracic aorta and femoral artery cannulated with ¾ th size tubing in between (Figure 8). Aorta clamped distal to descending thoracic aorta canula. Both common iliac arteries also clamped. Aneurysm opened with cautery (Figure 9) and large 8 cm by 8 cm aortic thrombus evacuated (Figure 10). End to end aorto biiliac grafting done using 24 mm by 9 mm Y graft (Figure 11). The right renal artery was cannulated using a coronary canula and cold ringer lactate was infused to maintain cold ischemia of the right kidney during the entire procedure. Right renal artery then anastomosed directly on the graft. Incision closed with two drains, one in abdomen and other in left pleural cavity (Figure 12). Patient extubated

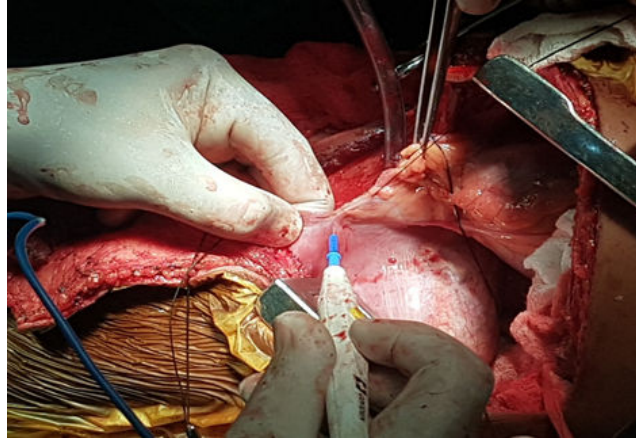
after 6 h and discharged after ten days. Cultures of the aortic wall and thrombus all yielded negative results for bacteria and fungi including TB and brucellosis. The patient recovered well post-operatively and had palpable bilateral pedal pulses. She was discharged from the hospital on the 10<sup>th</sup> day post-operatively in excellent condition and an ABI of 1.0 bilaterally. By 2 weeks post-op, she was mobilizing with no difficulty and her back pain had disappeared. A follow up ultrasound abdomen showed no collection in the peritoneum/retroperitoneum and a patent functioning aorto biiliac graft and a left iliorenal graft .



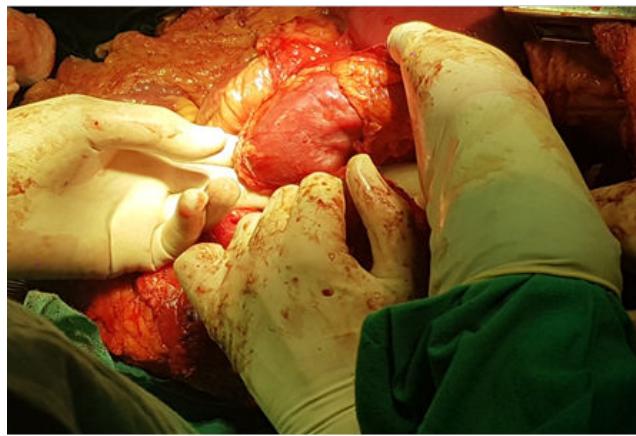
**Figure 1:** Contrast enhanced CT scan with an aortogram demonstrated a 8 × 8 cm partially thrombosed pseudoaneurysm just after the origin of superior mesenteric artery extending to both the common iliac artery origin.



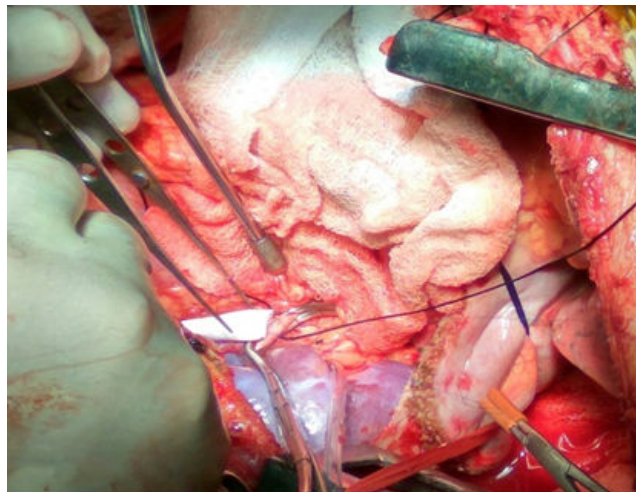
**Figure 2:** Marking of left thoracoabdominal incision.



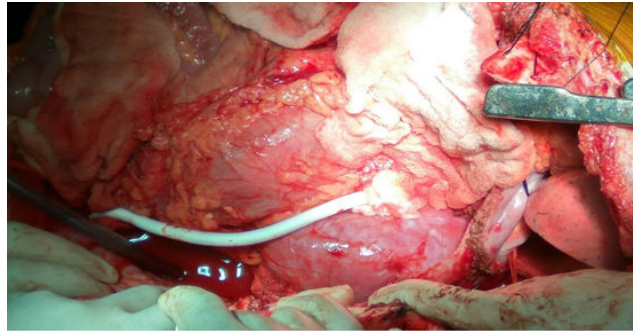
**Figure 3:** Cutting of diaphragm with cautery.



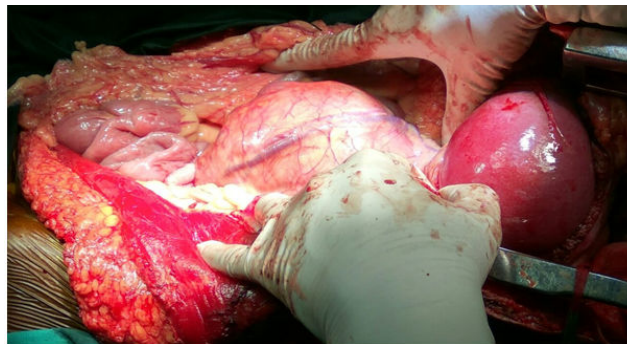
**Figure 4:** Mobilising left kidney.



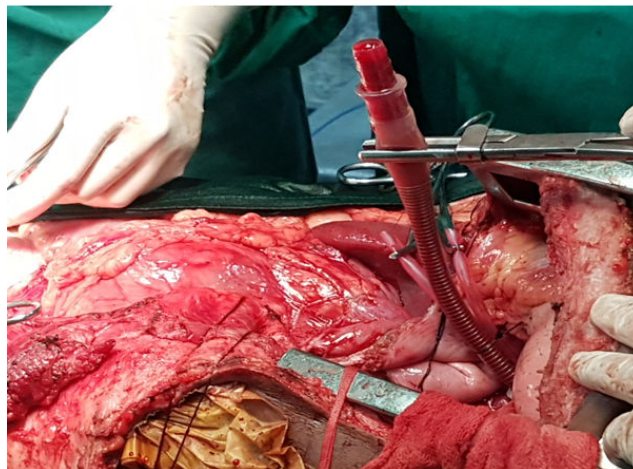
**Figure 5:** Suturing of 6 mm PTFE graft to left renal artery.



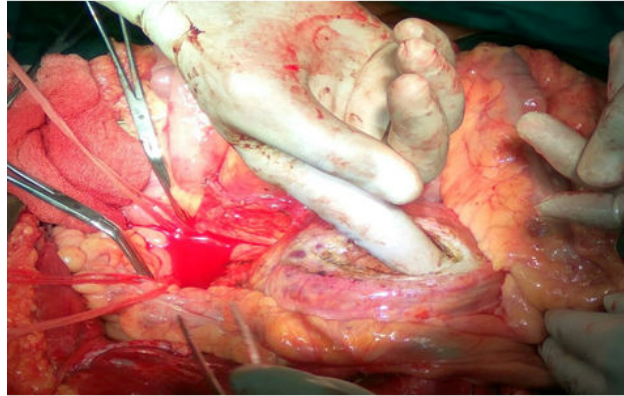
**Figure 6:** Left Ileorenal bypass grafting with 6 mm PTFE graft.



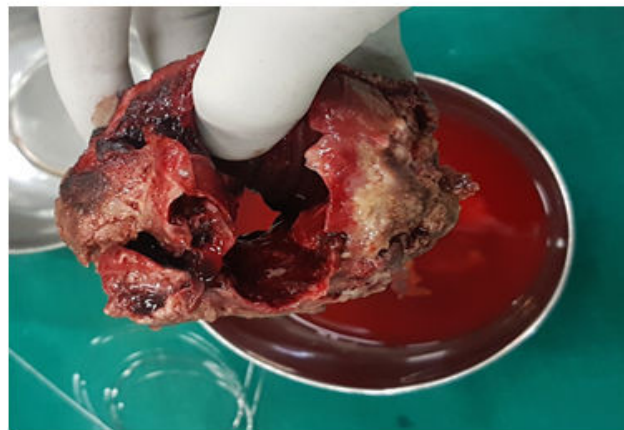**Figure 7:** Abdominal aortic aneurysm.



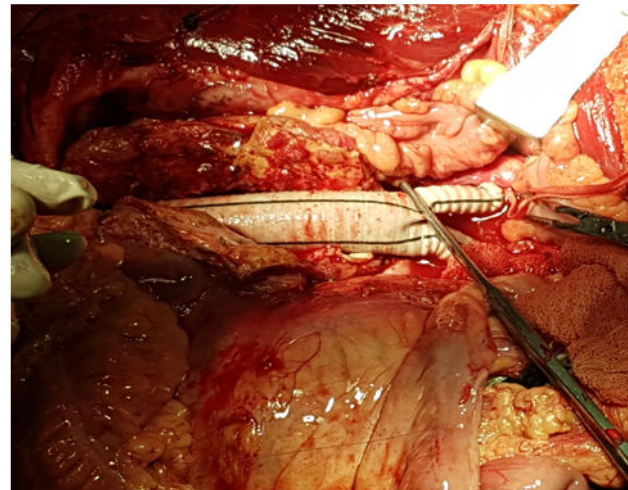
**Figure 8:** Cannulating descending thoracic aorta above the diaphragm.



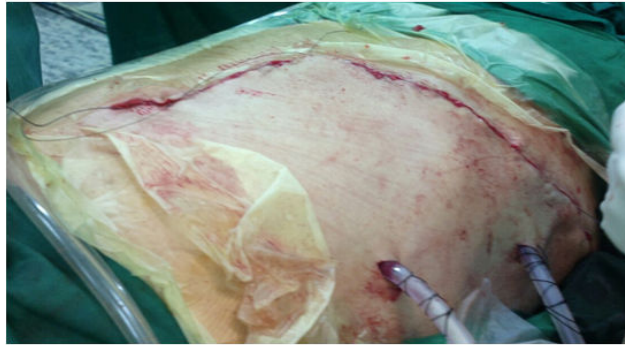**Figure 9:** Aneurysm opened with cautery.



**Figure 10:** Excised thrombus from aneurysm.



**Figure 11:** End to end aortobiliac Y grafting.



**Figure 12:** Closed left thoracoabdominal incision.